

Comparison of two cone beam computed tomographic systems versus panoramic imaging for localization of impacted maxillary canines and detection of root resorption

Ali Algerban*, Reinhilde Jacobs**, Steffen Fieuws*** and Guy Willems*

*Department of Orthodontics, **Oral Imaging Center and ***L-BioStat, Katholieke Universiteit Leuven, Belgium

Correspondence to: Professor Guy Willems, Department of Orthodontics, Faculty of Medicine, School of Dentistry, Oral Pathology and Maxillo-Facial Surgery, Katholieke Universiteit Leuven, Kapucijnenvoer 7, B-3000 Leuven, Belgium. E-mail: guy.willems@med.kuleuven.be

SUMMARY The diagnostic accuracy for the localization of impacted canines and the detection of canine-induced root resorption of maxillary incisors were compared between conventional radiographic procedures using one two-dimensional (2D) panoramic radiograph with that of two three-dimensional (3D) cone beam computed tomography (CBCT) scans. The clinical records of 60 consecutive patients who had impacted or ectopically erupting maxillary canines were identified from those seeking orthodontic treatment. For each case, two sets of radiographic information were obtained. The study sample was divided into two groups: group A ($n = 30$) included those for whom a dental pantomograph (DPT) and CBCT obtained with a 3D Accuitomo-XYZ Slice View Tomograph® were available and group B ($n = 30$) who had a DPT and CBCT obtained with a Scanora®. The DPT and CBCT images were subsequently analysed by 11 examiners. Statistical analysis included an evaluation of the agreement between observers based on the standard error of the measurement, kappa statistics and coefficient of concordance, as well as an assessment of the differences between 2D and 3D imaging employing Wilcoxon signed rank and McNemar tests.

There was a highly significant difference between the 2D and 3D images in the width of the canine crown ($P < 0.001$) and in canine angulation to the occlusal plane. Moreover, there was a highly significant difference between the DPT and Scanora CBCT images in canine angulation to the midline ($P < 0.001$). There was also a significant difference between 2D and 3D images with respect to canine location ($P = 0.0074$ for group A and $P = 0.0008$ for group B). The presence or absence of root resorption of the lateral incisor was also significantly different in both groups ($P = 0.0201$ and $P < 0.001$ for groups A and B, respectively). Detection of central incisor root resorption was significantly different between the Accuitomo and DPT images ($P = 0.045$). There was also a significant difference in the severity of lateral incisor root resorption between the DPT and CBCT in both groups ($P = 0.02$). The results of this study suggest that CBCT is more sensitive than conventional radiography for both canine localization and identification of root resorption of adjacent teeth.

Introduction

Impacted maxillary canines are frequently encountered and treated in orthodontic clinical practice. Treatment of impacted canines is lengthy and potentially difficult. The permanent maxillary canine is the second most frequently impacted tooth after the third molar, with a prevalence between 1 and 3 per cent (Ericson and Kurol, 1987a, 1988b; Eleftheriadis and Athanasiou, 1996; Preda *et al.*, 1997; Stewart *et al.*, 2001). However, in contrast to the third molar, the maxillary canine is located in a highly demanding area both aesthetically and functionally (Fernandez *et al.*, 1998). Both ectopically and palatally displaced erupting canines are seen more frequently in females than in males (Peck *et al.*, 1994; Leifert and Jonas, 2003) and there is a wide variation among different racial populations (Kramer and

Williams, 1970; Thilander and Myrberg, 1973; Peck *et al.*, 1994). The aetiology of impacted canines is multifactorial and still unclear. According to some authors, genetic and local factors might play a role in palatally impacted canines (Becker *et al.*, 1981; Jacoby, 1983; Bishara, 1992; Peck *et al.*, 1994). Peg-shaped, missing, or short-root lateral incisors have been shown to be associated with this phenomenon (Becker *et al.*, 1981, 1984; Jacoby, 1983; Brin *et al.*, 1993). Moreover, maxillary canines have the longest and the most complicated eruption path of all teeth. Between the age of 5 and 15 years, the total eruption path extends over 22 mm (Coulter and Richardson, 1997), which causes the maxillary canines to be prone to deviations from the normal path of eruption (Becker *et al.*, 1984; Ericson and Kurol, 1987b; Bjerklin and Ericson, 2006).

Mismanagement and inaccurate diagnosis may cause complications during the development and eruption of an impacted canine. The most frequent adverse effect of canine impaction is resorption of the maxillary lateral incisor. Furthermore, the central incisor may be involved, and occasionally, resorption of premolars has been reported (Postlethwaite, 1989; Cooke and Nute, 2005; Walker *et al.*, 2005). In many cases, lateral incisor root resorption may be radiographically diagnosed at an early stage, but the resorption process often remains asymptomatic, even in cases of pulpal involvement (Ericson and Kurol, 2000b). When root resorption is clinically diagnosed at an advanced stage, it makes treatment difficult and may lead to extraction of the affected tooth (Ericson and Kurol, 2000a; Stivaros and Mandall, 2000).

Until recently, conventional two-dimensional (2D) radiographic imaging was the most common modality used clinically as the primary diagnostic radiograph for the localization of impacted canines, treatment planning, and evaluation of the treatment result. Panoramic radiography is a standard diagnostic tool in orthodontics for the pre-operative diagnosis of routine cases. The diagnostic accuracy and validity for localizing impacted canines and adjacent structures can be underestimated due to deficiencies, such as distortion projection errors, blurred images, and complex maxillofacial structures that are projected onto a 2D plane, thus increasing the risk of misinterpretation (Ericson and Kurol, 1987a, 1988a; Peene *et al.*, 1990; Elefteriadis and Athanasiou, 1996; Stewart *et al.*, 2001).

Correct treatment planning requires accurate diagnosis and localization of the impacted canine in relation to adjacent structures (Preda *et al.*, 1997; Walker *et al.*, 2005; Liu *et al.*, 2008). Assessing root resorption and changes in root surface morphology normally requires three-dimensional (3D) information. Several authors have therefore suggested the use of computed tomography (CT) in such cases (Peene *et al.*, 1990; Schmuth *et al.*, 1992; Ericson and Kurol, 1988a, 2000a; Ericson *et al.*, 2002), since CT overcomes the limitations of conventional radiography and increases the detection rate of root resorption by 50 per cent (Ericson and Kurol, 2000b). CT was found to be superior to conventional radiographs for the localization of impacted canines and in the assessment of incisor root resorption (Schmuth *et al.*, 1992; Preda *et al.*, 1997; Ericson and Kurol, 2000a; Stewart *et al.*, 2001; Heimisdottir *et al.*, 2005). CT was developed for medical applications, and the effective dose is much higher than that of conventional 2D radiography, and the procedure is relatively expensive. Thus, using CT for the routine analysis of impacted canines is largely unjustified (Schmuth *et al.*, 1992; Preda *et al.*, 1997; Scarfe *et al.*, 2006).

Recently, cone beam computed tomography (CBCT) units have been introduced with reduced radiation exposure and 3D imaging capability for dental structures. The different devices vary in the field of volume and resolution

of the area of interest. Many questions regarding both panoramic imaging and CBCT need to be addressed. However, there has been no direct comparison of panoramic imaging and CBCT, and no data are available on whether 3D imaging provides significantly more information than traditional radiographs, concerning the diagnosis of root resorption and localization of impacted canines. Therefore, the purpose of this retrospective study was to compare the radiographic diagnostic accuracy of CBCT with that of panoramic radiography for the localization of impacted maxillary canines and incisor root resorption lesions.

Materials and methods

The clinical records of 60 consecutive patients who had impacted or ectopically erupting maxillary canines were identified from those seeking orthodontic treatment at the Division of Orthodontics, Katholieke Universiteit Leuven. A total of 89 impacted maxillary canines were studied. The patients were 37 females and 23 males, with ages ranging from 6.3 to 28.9 years [mean: 13.2, median: 12.2, standard deviation (SD): 4.2].

For the purpose of this study, two groups were formed. For each subject, two sets of radiographic information had been obtained within a maximum interval of 2 weeks. The first set consisted of traditional panoramic radiographs and the second set 3D volumetric images obtained from a CBCT scan. Group A ($n = 30$) included those patients who had a dental pantomograph (DPT) and CBCT obtained with a 3D Accutomo-XYZ Slice View Tomograph® (J. Morita, Kyoto, Japan) and group B ($n = 30$) who had a DPT and CBCT obtained with a Scanora® 3D CBCT (Soredex, Tuusula, Finland).

The panoramic exposures were made using a Cranex Tome® (Soredex). The exposure parameters were 15 seconds, 65 kV, and 15 mA, using 15×30 cm Agfa storage phosphor plates (MD10XHQ®, Agfa, Mortsels, Belgium), and the scan was read by an ADC Solo® phosphor plate scanner (Agfa). The magnification factor was 1:3. Each DPT image was extracted from the original software and saved as a JPEG file. The stored images were viewed and measured using Adobe® Photoshop® (version 7.0, San Jose, California, USA).

CBCT images were acquired at the Oral Imaging Centre, Katholieke Universiteit Leuven. Examination of the CBCT scans was performed using two systems. For the 3D Accutomo-XYZ, a voxel size of 0.125 mm (field of volume 30×40 mm) was used. Parameters included a tube voltage of 80 kV, a tube current of 3 mA, and a scanning time of 18 seconds. The images were viewed and measured with i-Dixel One Data Viewer Version 1.27 software (J. Morita). For the Scanora 3D CBCT, the voxel size was 0.2 mm (field of volume 75×100 mm) with tube voltage of 85 kV, current of 15 mA, and a scanning time of 3.7 seconds.

In a pilot study, the ‘medium field of volume’ and ‘high resolution’ were tested and selected to provide improved image quality for detecting root resorption rather than ‘small’ and ‘large fields of volume’. The images were viewed and measured using the OnDemand3D®™ application, version 1.0 software (CyberMed Inc., Seoul, South Korea). All exposures were performed by the same technical operator.

DPT and CBCT images were produced and subsequently analysed by two groups of examiners. The first group comprised three experienced dental practitioners and the second group eight postgraduates with a mean age of 27 years. The standardized protocol was explained to the observers. All observers received instructions and a demonstration before the data acquisition so that a standardized evaluation could be maintained. There was no significant difference with respect to experience using the CBCT viewer between the various observers.

Radiographic evaluation of images

One hundred and twenty sets of images were reviewed and analysed by each investigator in a random order. The observers examined 60 DPT images and 30 images of each type of CBCT. They were instructed to manipulate the images with the software enhancement tools according to their own preference.

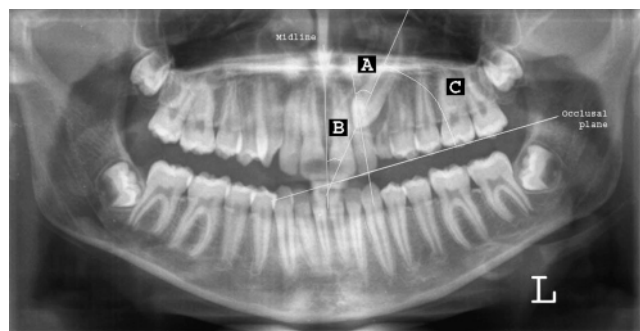


Figure 1 Panoramic view illustrating reference lines and angular measurements. (A) Angle of impacted canine to the lateral incisor, (B) angle of impacted canine to midline, and (C) angle of impacted canine to occlusal plane.

The evaluation process involved two questionnaires. The first group of observers recorded the following variables:

1. Width of the permanent maxillary canine crown in millimetres measured from the mesial contour of the maxillary canine to the distal contour.
2. Width of the permanent maxillary canine follicle in millimetres defined as the largest distance from the cusp tip of the canine to the periphery of the follicle with the long axis.
3. Development of the permanent maxillary canine was assigned to four categories based on root development: complete development; two-thirds of the root developed; one-half of the root developed; and one-quarter of the root developed.
4. Permanent maxillary canine angulations. Three angles were measured for the localization of an impacted canine as follows—(a) Canine angulation to the lateral incisor: The angles were measured between the two lines formed by a line through the canine cusp and the apex bisecting the long axis of the impacted canine and a line through the apex of the lateral incisor and the mid crown bisecting the long axis of the lateral incisor (Ericson and Kurol, 1987b, 1988b; Figures 1 and 2). (b) Canine angulation to the midline: The angles measured were formed by a line bisecting the midline of the jaws and a line through the canine cusp and the apex bisecting the long axis of the impacted canine (Ericson and Kurol, 1987b, 1988b; Walker *et al.*, 2005; Liu *et al.*, 2008; Figures 1 and 2). (c) Canine Angulation to the occlusal plane: The angles measured were formed by a line through the canine cusp and the apex bisecting the long axis of the impacted canine and the occlusal plane (Ericson and Kurol, 1987b, 1988b; Walker *et al.*, 2005; Liu *et al.*, 2008; Figures 1 and 2).
5. Primary maxillary canines were assigned to one of four categories as suggested by Ericson *et al.* (2002): (a) missing, where the primary canine had been extracted; (b) no resorption of the primary maxillary canines; (c) resorbed root, without contact between the follicle of the permanent and primary canines; and (d) resorbed root, with contact between the follicle of the permanent and primary canines.

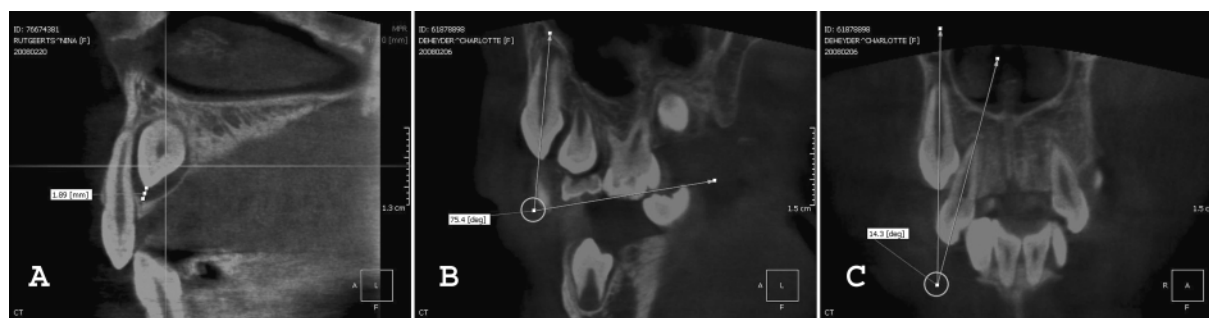


Figure 2 Cone beam computed tomographic (CBCT) views from the Scanora® three-dimensional CBCT system illustrating (A) canine follicle width in millimetres, (B) angle of impacted canine to occlusal plane, and (C) angle of impacted canine to the lateral incisor.

6. Permanent maxillary canine location in relation to adjacent teeth palatally, buccally, or in the line of the arch.
7. Contact relationship between the canines and incisors. The contact relationship between permanent maxillary canines and incisors was assigned to one of two categories (Ericson *et al.*, 2002)—(a) contact: the distance between the crown of the permanent maxillary canines and adjacent incisors was less than 1 mm and (b) no contact: the distance between the crown of the permanent maxillary canines and adjacent incisors was more than 1 mm.
8. Severity of root resorption. The examiners were asked to determine whether they could detect a resorption defect in the lateral incisor. If resorption was diagnosed, the severity of resorption was rated based on the grading systems suggested by Ericson *et al.* (2002)—(a) no resorption: intact root surfaces; (b) slight resorption: resorption extending up to half of the dentine thickness to the pulp; (c) moderate resorption: resorption midway to the pulp or more with the pulp lining being intact; and (d) severe resorption: the pulp is exposed by the resorption.
9. Location of resorption. The location of the diagnosed resorption defect was also recorded as in the apical, middle, or cervical third.

The second group of observers completed a questionnaire related only to variables 5–9.

Statistical analysis

Agreement between observers. For measurements of width and angulations, the agreement between the three observers was quantified using the standard error of measurement (SEM), which is the standard deviation (SD) of the measurements within a patient. A SEM equal to 0.5 implies that, for a specific patient, 95 per cent of the obtained values (from various observers) are expected to fall in a range of $\pm 1.96 \times 0.5$ around the true value. The SD of the difference between two values obtained from two observers is as follows:

$$\sqrt{0.5^2 + 0.5^2} = 0.707$$

Within-patient variability can also be expressed as an unitless measure:

1. Expressing the SEM relative to the mean of the measurements, which is known as within-subject coefficient of variation (WSCV).
2. Taking the ratio of the total variance minus the squared SEM over the total variance. This ratio is known as the intraclass correlation (ICC).

For the nominal and ordinal scorings, proportions of raw agreement (overall and specific to each category level) were also evaluated. A kappa coefficient for multiple raters was also quantified to assess inter-observer agreement. Kappas are constructed for overall agreement using the SAS-macro

percentage mkappa (version 9.2, SAS Institute Inc., Cary, North Carolina, USA). For the ordinal scores, Kendall's coefficient of concordance is reported.

Assessment of the differences between 2D and 3D imaging. All measurements on panoramic radiographs were divided by the magnification factor of 1:3. The measurements of the width and angulation were compared between the 2D and 3D images using a non-parametric Wilcoxon signed rank test on the mean measurement of the three observers. Since this test treats bilateral and unilateral cases equally, the robustness of the conclusion was verified using a linear mixed model. For categorical responses, tests of symmetry were used for each observer separately to explore differences. Furthermore, instead of performing observer-specific analyses, the modus (over the observers) of the scores was used to compare the 2D and 3D images. All comparisons between the 2D and 3D images were undertaken separately on the set of patients' data. *P*-values less than 0.05 were considered significant.

Results

The distribution of the number of impacted canines diagnosed in the 60 patients is given in Table 1. The mean values for the linear and angular measurements, the SEM, and ICC are shown in Table 2. Table 3 displays the percentages of the total number of a reproducibility of agreement for all diagnostic variables for each patient in groups A and B (Accuitomo CBCT versus DPT and Scanora CBCT versus DPT, respectively).

The root resorptions detected in the lateral and central incisors are shown in Table 4. Compared with panoramic radiography, lateral incisor root resorption cavities were more distinguishable using CBCT (Table 4). Greater agreement between observers for all variables was achieved when using CBCT. The results show that the proportion of agreement was high for the assessment of CBCT images (Table 5). For the presence of lateral incisor root resorption, Kendall's coefficient of concordance for an ordinal response was 0.48 for the Accuitomo and Scanora images and 0.41 for the DPT images. The value for central incisor

Table 1 Distribution of the 89 impacted maxillary canines and percentage for group A: patients who had a dental pantomograph (DPT) and cone beam computed tomogram obtained with Accuitomo; group B: patients who had a DPT and cone beam computed tomography obtained with Scanora.

	Male	Female	Bilateral	Unilateral	Right	Left
Group A	12 40%	18 60%	9 30%	21 70%	17 44%	22 56%
Group B	11 37%	19 63%	20 67%	10 33%	25 50%	25 50%

Table 2 Agreement between the three experienced observers for linear measurements of width in millimetres and angulations for the three different imaging systems: panoramic, Accuitomo three-dimensional (3D) cone beam computed tomography (CBCT), and Scanora 3D CBCT.

Measurement	Set	Mean	Between-patient standard deviation (SD)	Standard error of measurement	Intraclass correlation	Within-unit coefficient of variation (%)
Width of canine dental follicle	Accuitomo	0.83	0.76	0.35	0.83	41.8
	Scanora	0.99	0.65	0.48	0.65	47.7
	Panoramic	1.03	0.48	0.62	0.37	60.2
Width of canine crown	Accuitomo	7.96	0.61	0.41	0.69	5.1
	Scanora	7.92	0.36	0.55	0.30	6.9
	Panoramic	8.78	1.20	0.61	0.79	6.9
Canine angle to lateral incisor	Accuitomo	30.30	17.93	5.61	0.91	18.5
	Scanora	31.58	14.40	4.75	0.90	15.0
	Panoramic	33.28	18.19	3.33	0.96	10.0
Canine angle to midline	Accuitomo	25.45	13.88	7.57	0.77	29.7
	Scanora	14.52	12.33	3.76	0.91	25.9
	Panoramic	24.07	17.05	3.72	0.95	15.4
Canine angle to occlusal plane	Accuitomo	63.09	12.27	9.68	0.62	15.3
	Scanora	62.43	9.04	4.94	0.77	7.9
	Panoramic	55.80	18.11	4.69	0.94	8.4

All measurements in millimetres of the panoramic radiographs are divided by the magnification factor of 1:3.

Table 3 Overall agreement level for each variable in terms of percentage in each patient group.

		Group A		Group B	
		Accuitomo (%)	Panoramic (%)	Scanora (%)	Panoramic (%)
Canine development	Complete	50.4	58.9	44.7	36.7
	2/3 of the root	5.1	11.1	6.6	15.3
	1/2 of the root	35.0	27.4	48.7	48.0
	1/4 of the root	9.5	2.6	0	0
Primary canine	No resorption	11.4	18.2	39.2	35.9
	Resorption without contact	56.0	47.9	19.6	32.6
	Resorption with contact	32.6	33.9	41.2	31.5
Canine location	Line of the arch	22.1	35.7	21.8	36.7
	Palatally	39.2	45	34.0	42.7
	Bucally	38.7	19.3	44.2	20.6
Contact with the lateral incisor	Contact	89.0	73.9	92.5	84.0
	No contact	11.0	26.1	7.5	16.0
Severity of resorption of the lateral incisor	No resorption	46.1	70.6	49.1	69.3
	Slight resorption	35.9	18.0	39.8	19.1
	Moderate resorption	9.9	6.0	5.1	4.3
	Severe resorption	8.1	5.4	6.0	7.3
Location of resorption of the lateral incisor	Apical	26.6	14.2	21.5	15.1
	Middle	19.6	13.3	28.0	14.2
	Cervical	7.8	2.1	1.3	1.1
Contact with the central incisor	Contact	23.8	31.7	16.0	19.5
	No contact	76.2	68.3	84.0	80.5
Severity of resorption of the central incisor	No resorption	84.9	87.0	95.1	94.5
	Slight resorption	7.9	5.1	4.7	3.8
	Moderate resorption	1.4	2.1	0.2	0.5
	Severe resorption	5.8	5.8	0	1.2
Location of resorption of the central incisor	Apical	8.7	6.1	3.1	2.7
	Middle	6.7	6.8	1.3	2.7
	Cervical	0.5	0	0.4	0

root resorption was 0.72 for Accuitomo, 0.43 for Scanora, and 0.34 for DPT images. The comparison of linear measurements and angulations between 2D and 3D are shown in Table 6.

Based on the analysis using the protocol (over the observers) for the categorical outcomes, there was only evidence for a difference between 2D and 3D imaging with respect to canine location; $P = 0.0074$ for group A and $P = 0.0008$ for

Table 4 Overall agreement level of the detection of root resorption of the maxillary incisors in terms of percentage for each patient group.

		Group A		Group B	
		Accuitomo (%)	Panoramic (%)	Scanora (%)	Panoramic (%)
Lateral incisor	No resorption	46.1	70.6	49.1	69.3
	Resorption	53.9	29.4	50.9	30.7
Central incisor	No resorption	84.9	87.0	95.1	94.5
	Resorption	15.1	13.0	4.9	5.5

Table 5 Reproducibility level of the proportion of agreement and kappa coefficient of inter-observer agreement between 11 observers for scoring each variable for the three different image systems: panoramic, Accuitomo three-dimensional (3D) cone beam computed tomography (CBCT), and Scanora 3D CBCT.

		Accuitomo	Scanora	Panoramic
Canine development	Proportion of agreement	0.84	0.81	0.71
	Kappa	0.74	0.66	0.53
	Standard error	0.06	0.06	0.04
Primary canine	Proportion of agreement	0.80	0.65	0.54
	Kappa	0.65	0.44	0.32
	Standard error	0.03	0.02	0.01
Canine location	Proportion of agreement	0.79	0.76	0.56
	Kappa	0.68	0.63	0.31
	Standard error	0.01	0.01	0.01
Contact with the lateral incisor	Proportion of agreement	0.86	0.92	0.73
	Kappa	0.31	0.42	0.18
	Standard error	0.02	0.01	0.01
Detection of root resorption of the lateral incisor	Proportion of agreement	0.65	0.63	0.48
	Kappa	0.24	0.26	0.26
	Standard error	0.02	0.01	0.01
Location of resorption of the lateral incisor	Proportion of agreement	0.53	0.53	0.65
	Kappa	0.30	0.26	0.26
	Standard error	0.01	0.01	0.01
Contact with the central incisor	Proportion of agreement	0.88	0.90	0.86
	Kappa	0.67	0.64	0.64
	Standard error	0.02	0.01	0.01
Detection of root resorption of the central incisor	Proportion of agreement	0.90	0.94	0.87
	Kappa	0.63	0.36	0.23
	Standard error	0.02	0.01	0.01
Location of resorption of the central incisor	Proportion of agreement	0.88	0.93	0.86
	Kappa	0.57	0.30	0.17
	Standard error	0.01	0.01	0.01

Table 6 Differences between linear measurement of width and angulations between the Accuitomo three-dimensional (3D) cone beam computed tomographic (CBCT) versus panoramic images and between the Scanora 3D (CBCT) versus panoramic images using the Wilcoxon signed rank test on the mean measurement of the three observers.

Measurement	Set	Difference	Standard deviation	<i>P</i> Wilcoxon	<i>P</i> -value
Width of the canine dental follicle	Accuitomo versus panoramic	-0.20	0.96	0.19631	0.1184
	Scanora versus panoramic	-0.03	0.75	0.93964	0.7573
Width of the canine crown	Accuitomo versus panoramic	-0.71	0.96	0.00003	<0.0001
	Scanora versus panoramic	-0.94	1.44	0.00001	<0.0001
Canine angle to the lateral incisor	Accuitomo versus panoramic	-2.52	10.60	0.38624	0.1412
	Scanora versus panoramic	-2.06	8.21	0.06531	0.0795
Canine angle to the midline	Accuitomo versus panoramic	-1.41	11.32	0.51005	0.4341
	Scanora versus panoramic	-7.38	8.60	9.22890	<0.0001
Canine angle to the occlusal plane	Accuitomo versus panoramic	7.61	17.79	0.00213	0.0101
	Scanora versus panoramic	6.39	13.01	0.00310	0.0010

group B. The detection of the presence or absence of root resorption of the lateral incisor was also significantly different in both groups ($P = 0.0201$ and $P < 0.001$, respectively). The detection of the presence of central incisor root resorption was significantly different between the Accuitomo and DPT images in group A ($P = 0.045$). There was also a significant difference in the severity of lateral incisor root resorption between the DPT and CBCT in both groups ($P = 0.02$).

Discussion

Patients with severe lateral incisor root resorption present treatment challenges to both orthodontists and maxillofacial

surgeons that may lead to time-consuming and expensive treatment, including surgical exposure and repositioning of the impacted canine. The choice of treatment is influenced by the site and severity of the root lesion. Previous studies addressing the issue of canine impaction-related root resorption date back more than 10 years. Meanwhile, CBCT has become commercially available and promises improved diagnosis of canine impaction as well as incisor root resorption. Over recent years, there have been many publications concerning the application of CBCT. Therefore, radiographic evaluation of CBCT and the potential influence of 3D information *in vivo* for diagnostic and preventive measures needs to be ascertained and requires validation through comparison with conventional methods.

DPTs were chosen as the conventional radiographs, because the panoramic radiograph is a common choice for the diagnosis and treatment planning of impacted canines for most patients undergoing routine orthodontic screening. Intraoral 2D radiography was not performed in this study to avoid further radiation exposure and because it has the same constraints as DPT imaging. In addition, intraoral 2D images have been found to be an inaccurate diagnostic tool for the detection of palatal root resorption of the incisor in cases without overlap (Follin and Lindvall, 2005). In the present study, patients with slight or non-resorbed lateral incisors were randomly selected. There were more females than males in the study, which is consistent with other reports (Ericson and Kurol, 1987a, 2000b). The incidence of palatally impacted canines appears to be twice that in females compared with males (Bishara, 1992). On the other hand, this could also be due to more females than males seeking orthodontic treatment (Leifert and Jonas, 2003).

Linear and angular measurements are frequently used as comparative parameters for radiological assessment. They were used in the present study due to their relative use as predictors of canine eruption (Ericson and Kurol, 1987b, 1988b; Power and Short, 1993; Stivaros and Mandall, 2000; Warford, *et al.*, 2003). Several authors have suggested that the linear measurement is a reliable method for panoramic radiographs, considering the magnification factors and correct patient position (Stramotas *et al.*, 2002; Laster *et al.*, 2005; Volchansky *et al.*, 2006). The patient position during DPT image acquisition was considered but the findings showed that it did not influence the results of this study, since all images were acquired by one operator, and a standardized patient position was maintained. The magnification factor was also considered by dividing all panoramic radiograph measurements by the magnification factor of 1:3. Compared with the CBCT images, the panoramic radiographs were less reliable and resulted in lower measurement accuracy and less agreement between the observers. This may have been the result of insufficient diagnosis of the surrounding anatomical structures and the fact that panoramic radiographs lack the third dimension. Deformations on panoramic images are not seen on 3D

CBCT. However, CBCT images were less influenced by patient position and free from the influence of the pattern of superimposition of the anatomical structures, which may have a significant influence on the measurement. Moreover, CBCT reconstruction allows greater accuracy and reliability for linear measurements (Lascala *et al.*, 2004) with improved visualization of the anatomical situation of the impacted maxillary canine. However, the results of the current study show that the linear measurement of the two imaging modalities was statistically different in the width of the canine crowns. This may occur because every system has various sources of display and measurement error. In DPT images, structures closer to the X-ray source appear more magnified than those closer to the detector, such as palatally impacted canines. The canine angle to the midline was statistically different between the Scanora and DPT images but not between the Accuitomo and panoramic radiograph. This could be a result of the small field of view of the Accuitomo system (30 × 40 mm). Re-slicing of the image at a vertical plane to the area of interest may prevent, in some cases, accurate determination of the midline. In agreement with Peck *et al.* (2007), it was found that the accuracy in determination of linear root angulations between the DPT and CBCT was not a reliable tool, particularly in the canine region.

The data of the present research clearly highlight the fact that the CBCT allowed validation of the impacted canine. The determination of canine location was highly significantly different between the DPT and CBCT systems because CBCT images provide applicable diagnostic information for canine location in the sagittal, axial, and coronal planes without overlap. This is in agreement with a recent study that found DPT images were not a reliable method for localization of impacted canines (Nagpal *et al.*, 2009).

The main aim of this study was to compare the detection of root resorption, which has shown significant differences among imaging modalities. Several authors have confirmed that root resorption of the maxillary incisors is more prevalent and more frequently related to impacted canines than is assumed when using 3D images (Ericson and Kurol, 2000b; Walker *et al.*, 2005; Liu *et al.*, 2008). Conventional radiographic imaging, such as DPT, has been found to be inadequate for the detection of root resorption and the characterization of resorption lesions (Ericson and Kurol, 1988a,b; Peene *et al.*, 1990; Heimisdottir *et al.*, 2005). In addition, the accuracy of assessing palatal or buccal root resorption of the lateral incisor using 2D images is restricted, especially in subjects with early or mild resorption (Ericson and Kurol, 1987b, 2000b; Preda *et al.*, 1997; Heimisdottir *et al.*, 2005). CBCT eliminates the problems with conventional tomography and substantially increases the perceptibility of detecting root resorption. Comparative studies have found that conventional panoramic radiography has a low reliability for diagnosing incisor root resorption associated with impacted canines compared with CT (Schmuth *et al.*, 1992; Freisfeld *et al.*, 1999). In addition, CBCT has proven superior to other radiographic methods for visualizing the maxillofacial

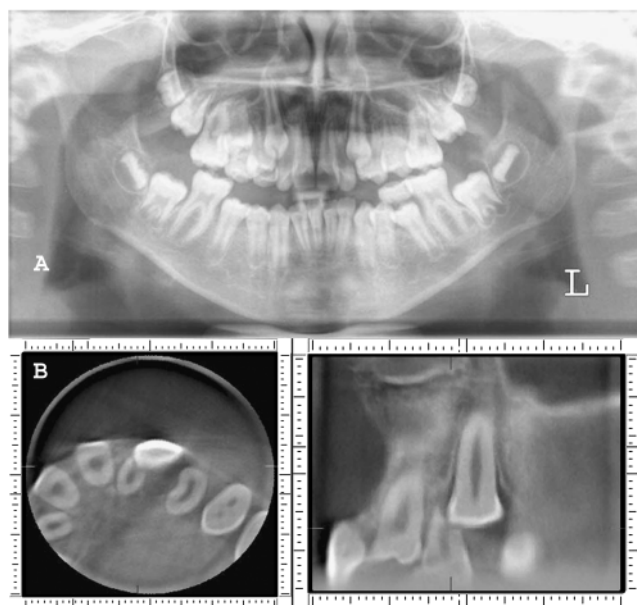


Figure 3 (A) Two-dimensional panoramic radiograph of an 11-year-old female with bilateral impacted maxillary canines with no sign of resorption of the left maxillary lateral incisor. The root contour of the lateral incisor overlaps that of the canine and is difficult to assess. (B) Three-dimensional (3D) cone beam computed tomographic image from the Accuitomo 3D system showing axial and coronal views of the left maxillary lateral incisor with severe root resorption of the cervical third.

region and to be a useful aid to both orthodontists and maxillofacial surgeons for diagnosing and visualizing the position and complications of ectopically erupting teeth (Scarfe *et al.*, 2006; Quereshy *et al.*, 2008). CBCT has also shown superior results to DPTs for imaging the temporomandibular joint and in localizing the lower third molars in relation to the mandibular canal (Honey *et al.*, 2007; Angelopoulos *et al.*, 2008). In the present study, CBCT was found to be more accurate than panoramic radiography for detecting root resorption (Figures 3 and 4), in agreement with the results of Dudic *et al.* (2009). Both CBCT systems were rated higher than DPTs for different diagnostic tasks. However, when there was no resorption, conventional DPTs were scored higher than the CBCT images (Figures 3 and 4). Both CBCT systems had a high proportion of agreement for severity of root resorption. The percentage of root resorption observed on primary canines, with or without contact with the permanent canine, was almost the same for all three imaging modalities tested. However, there was more agreement between the observers for the CBCT systems than for the DPTs in the presence of root resorption of the primary canine.

The radiation dose is always a matter of debate when using CT. However, the radiation dose of CBCT was found to be up to 98 per cent less than that for conventional CT (Scarfe *et al.*, 2006). In a pilot study, the highest effective dose was measured for the Accuitomo system at 44 μ Sv in

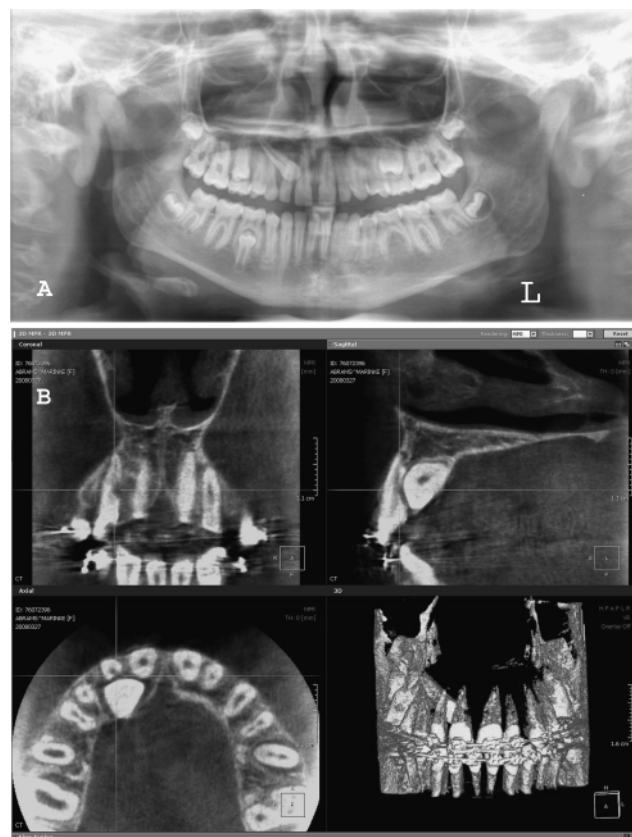


Figure 4 (A) Two-dimensional panoramic radiograph of a 16-year-old male with an impacted maxillary right canine with no sign of resorption of the right maxillary lateral incisor. The root contour of the lateral incisor overlaps with that of the canine and is difficult to assess. (B) Three-dimensional (3D) cone beam computed tomographic image from the Scanora® 3D system showing axial, sagittal, and coronal slices as well as a 3D model that were used to identify the impacted maxillary right canine and severe root resorption of the middle third of the right maxillary lateral incisor.

the maxilla for the canine and premolar regions and 26.6 μ Sv for the Scanora system using the medium field of view and high-resolution mode. The radiation dose of CBCT is 2–4 times the effective dose of the panoramic radiograph, which is between 4.7 and 14.9 μ Sv (Gijbels *et al.*, 2005).

Conclusion

Early radiographic examination and diagnosis are essential to recognize impacted canines. The sequela of delayed eruption or treatment of impacted canines may be severe resorption of the adjacent lateral and central incisors.

The use of CBCTs rather than DPT imaging for the assessment of impacted canines has a potential diagnostic effect and may influence the outcome of treatment. Such a technique of free overlap may increase the interpretation of treatment outcome and treatment progress. CBCT may be a reliable method for detecting canine impaction and root resorption of adjacent teeth. A CBCT image establishes the link between 2D and 3D imaging and is more accurate for the

different diagnostic tasks in canine impaction than panoramic radiography. Using CBCT with the maximum data available would help reduce unnecessary radiation exposure.

References

- Angelopoulos C, Thomas S, Hechler S, Parissis N, Hlavacek M 2008 Comparison between digital panoramic radiography and cone-beam computed tomography for the identification of the mandibular canal as part of presurgical dental implant assessment. *Journal of Oral and Maxillofacial Surgery* 66: 2130–2135
- Becker A, Smith P, Behar R 1981 The incidence of anomalous maxillary lateral incisors in relation to palatally-displaced cuspids. *Angle Orthodontist* 51: 24–29
- Becker A, Zilberman Y, Tsur B 1984 Root length of lateral incisors adjacent to palatally-displaced maxillary cuspids. *Angle Orthodontist* 54: 218–225
- Bishara S 1992 Impacted maxillary canines: a review. *American Journal of Orthodontics and Dentofacial Orthopedics* 101: 159–171
- Bjerklin K, Ericson S 2006 How a computerized tomography examination changed the treatment plans of 80 children with retained and ectopically positioned maxillary canines. *Angle Orthodontist* 76: 43–51
- Brin I, Becker A, Zilberman Y 1993 Resorbed lateral incisors adjacent to impacted canines have normal crown size. *American Journal of Orthodontics and Dentofacial Orthopedics* 104: 60–66
- Cooke M E, Nute S J 2005 Maxillary premolar resorption by canines: three case reports. *International Journal of Paediatric Dentistry* 15: 210–212
- Coulter J, Richardson A 1997 Normal eruption of the maxillary canine quantified in three dimensions. *European Journal of Orthodontics* 19: 171–183
- Dudic A, Giannopoulou C, Leuzinger M, Kiliaridis S 2009 Detection of apical root resorption after orthodontic treatment by using panoramic radiography and cone-beam computed tomography of super-high resolution. *American Journal of Orthodontics and Dentofacial Orthopedics* 135: 434–437
- Eleftheriadis J N, Athanasiou A E 1996 Evaluation of impacted canines by means of computerized tomography. *The International Journal of Adult Orthodontics and Orthognathic Surgery* 11: 257–264
- Ericson S, Bjerklin K, Falahat B 2002 Does the canine dental follicle cause resorption of permanent incisor roots? A computed tomographic study of erupting maxillary canines. *Angle Orthodontist* 72: 95–104
- Ericson S, Kurol J 1987a Incisor resorption caused by maxillary cuspids. A radiographic study. *Angle Orthodontist* 57: 332–346
- Ericson S, Kurol J 1987b Radiographic examination of ectopically erupting maxillary canines. *American Journal of Orthodontics and Dentofacial Orthopedics* 91: 483–492
- Ericson S, Kurol J 1988a CT diagnosis of ectopically erupting maxillary canines—a case report. *European Journal of Orthodontics* 10: 115–121
- Ericson S, Kurol J 1988b Resorption of maxillary lateral incisors caused by ectopic eruption of the canines. A clinical and radiographic analysis of predisposing factors. *American Journal of Orthodontics and Dentofacial Orthopedics* 94: 503–513
- Ericson S, Kurol J 2000a Incisor root resorptions due to ectopic maxillary canines imaged by computerized tomography: a comparative study in extracted teeth. *Angle Orthodontist* 70: 276–283
- Ericson S, Kurol P J 2000b Resorption of incisors after ectopic eruption of maxillary canines: a CT study. *Angle Orthodontist* 70: 415–423
- Ericson S, Bjerklin K, Falahat B 2002 Does the canine dental follicle cause resorption of permanent incisor roots? A computed tomographic study of erupting maxillary canines. *Angle Orthodontist* 72: 95–104
- Fernandez E, Bravo L A, Canteras M 1998 Eruption of the permanent upper canine: a radiologic study. *American Journal of Orthodontics and Dentofacial Orthopedics* 113: 414–420
- Follin M E, Lindvall A M 2005 Detection of lingual root resorptions in the intraoral radiographs. An experimental study. *Swedish Dental Journal* 29: 35–42
- Freisfeld M, Dahl I A, Jäger A, Drescher D, Schüller H 1999 X-ray diagnosis of impacted upper canines in panoramic radiographs and computed tomographs. *Journal of Orofacial Orthopedics* 60: 177–184
- Gijbels F, Jacobs R, Debaveye D, Bogaerts R, Verlinden S, Sanderink G 2005 Dosimetry of digital panoramic imaging. Part II: occupational exposure. *Dento Maxillo Facial Radiology* 34: 150–153
- Heimisdottir K, Bosshardt D, Ruf S 2005 Can the severity of root resorption be accurately judged by means of radiographs? A case report with histology. *American Journal of Orthodontics and Dentofacial Orthopedics* 128: 106–109
- Honey O B *et al.* 2007 Accuracy of cone-beam computed tomography imaging of the temporomandibular joint: comparisons with panoramic radiology and linear tomography. *American Journal of Orthodontics and Dentofacial Orthopedics* 132: 429–438
- Jacoby H 1983 The etiology of maxillary canine impactions. *American Journal of Orthodontics* 84: 125–132
- Kramer R M, Williams A C 1970 The incidence of impacted teeth: a survey at Harlem hospital. *Oral Surgery, Oral Medicine, Oral Pathology* 29: 237–241
- Lascaia C A, Panella J, Marques M M 2004 Analysis of the accuracy of linear measurements obtained by cone beam computed tomography (CBCT-NewTom). *Dento Maxillo Facial Radiology* 33: 291–294
- Laster W S, Ludlow J B, Bailey L J, Hershey H G 2005 Accuracy of measurements of mandibular anatomy and prediction of asymmetry in panoramic radiographic images. *Dento Maxillo Facial Radiology* 34: 343–349
- Leifert S, Jonas I E 2003 Dental anomalies as a microsymptom of palatal canine displacement. *Journal of Orofacial Orthopedics* 64: 108–120
- Liu D G, Zhang W L, Zhang Z Y, Wu Y T, Ma X C 2008 Localization of impacted maxillary canines and observation of adjacent incisor resorption with cone-beam computed tomography. *Oral Surgery, Oral Medicine, Oral Pathology, Oral Radiology and Endodontics* 105: 91–98
- Nagpal A, Pai K M, Setty S, Sharma G 2009 Localization of impacted maxillary canines using panoramic radiography. *Journal of Oral Science* 51: 37–45
- Peck J L, Sameshima G T, Miller A, Worth P, Hatcher D C 2007 Mesiodistal root angulation using panoramic and cone beam CT. *Angle Orthodontist* 77: 206–213
- Peck S, Peck L, Kataja M 1994 The palatally displaced canine as a dental anomaly of genetic origin. *Angle Orthodontist* 64: 249–256
- Peene P *et al.* 1990 Resorption of the lateral maxillary incisor: assessment by CT. *Journal of Computer Assisted Tomography* 14: 427–429
- Postlethwaite K M 1989 Resorption of premolar roots by ectopic canines. *British Dental Journal* 167: 397–398
- Power S M, Short M B 1993 An investigation into the response of palatally displaced canines to the removal of deciduous canines and an assessment of factors contributing to favourable eruption. *British Journal of Orthodontics* 20: 215–223
- Preda L *et al.* 1997 The use of spiral computed tomography in the localization of impacted maxillary canines. *Dento Maxillo Facial Radiology* 26: 236–241
- Quereshy F A, Savell T A, Palomo J M 2008 Applications of cone beam computed tomography in the practice of oral and maxillofacial surgery. *Journal of Oral and Maxillofacial Surgery* 66: 791–796
- Scarfe W C, Farman A G, Sukovic P 2006 Clinical applications of cone-beam computed tomography in dental practice. *Journal of the Canadian Dental Association* 72: 75–80
- Schmuth G P, Freisfeld M, Koster O, Schuller H 1992 The application of computerized tomography (CT) in cases of impacted maxillary canines. *European Journal of Orthodontics* 14: 296–301
- Stewart J A, Heo G, Glover KE, Williamson PC, Lam EW, Major PW 2001 Factors that relate to treatment duration for patients with palatally impacted maxillary canines. *American Journal of Orthodontics and Dentofacial Orthopedics* 119: 216–225

- Stivaros N, Mandall N A 2000 Radiographic factors affecting the management of impacted upper permanent canines. *Journal of Orthodontics* 27: 169–173
- Stramotas S, Geenty J P, Petocz P, Darendeliler M A 2002 Accuracy of linear and angular measurements on panoramic radiographs taken at various positions *in vitro*. *European Journal of Orthodontics* 24: 43–52
- Thilander B, Myrberg N 1973 The prevalence of malocclusion in Swedish schoolchildren. *Scandinavian Journal of Dental Research* 81: 12–21
- Volchansky A, Cleaton-Jones P, Drummond S, Bönecker M 2006 Technique for linear measurement on panoramic and periapical radiographs: a pilot study. *Quintessence International* 37: 191–197
- Walker L, Enciso R, Mah J 2005 Three-dimensional localization of maxillary canines with cone-beam computed tomography. *American Journal of Orthodontics and Dentofacial Orthopedics* 128: 418–423
- Warford J H J R, Grandhi R K, Tira D E 2003 Prediction of maxillary canine impaction using sectors and angular measurement. *American Journal of Orthodontics and Dentofacial Orthopedics* 124: 651–655